



**PATIENT**

Bax Bough

**SPECIES**

Feline

**BREED**

DLH

**SEX**

MN

**AGE**

14yr

**WEIGHT**

15.45lb

**PRESENTING CLINICAL SIGNS**

Sibling diagnosed w/cardiomyopathy- prescribed atenolol. Two siblings diagnosed with renal disease. Pet has a history of grade 1-2 heart murmur, but none auscultated recently. Meds: Adequan once monthly. Needs Dental- ok candidate for anesthesia?

Abnormal PE/Chem/CBC/UA Results: WNL CBC/Chem 9.25.25. BP: Doppler: 134mmHg/138mmHg, 138mmHg.

**ULTRASONOGRAPHIC EXAMINATION OF THE HEART**

FELINE CARDIAC PARAMETERS	BODY WEIGHT (kg)	HR (BPM)	IVSd (cm)	LVIDd (cm)	LVWd (cm)	FS (%)	EF (%)
NORMAL PARAMETER	-----	150-240	0.3-0.6	1.0-2.1	0.25-0.6	35-67	80-100
PATIENT	--	203	0.54	1.9	0.49	48	82
FELINE CARDIAC PARAMETERS	LA/AO M-Mode	LA/AO HEART BASE (Sisson)	LAD LA MAX 4 Chamber		LVOT VEL. (m/s)	RVOT VEL. (m/s)	IVRT (m/)
NORMAL PARAMETER	<1.5	1.6	0.7-1.7		<1.6	<1.3	40-60
PATIENT	--	1.45	1.7		1.5	1.2	NM

Sisson D et al. JVIM 1991; 5: 232, Jacobs et al. Am J Vet Res 1985; 46:1705

**INTERPRETED BY**

R. McKenzie Daniel, DVM, DABVP (Canine and Feline)

**IMAGING PERFORMED BY**

Rebecca Hamilton

**HOSPITAL NAME**

Creekside VC Oregon

**REFERRING VET**

Dr Matteson

**INVOICE**  
23456

**DATE**

01/05/2026

**Cardiac Presentation**

The echocardiogram in this patient demonstrated normal left atrial size and structure. Chamber volume and blood echogenicity were normal, no LA spontaneous contrast. The cranial and caudal mitral valve leaflets presented minor irregular age-related changes that are not clinically significant at this time with adequate extension in systole and union in diastole. No obvious MR on Doppler. The left ventricle presented normal free wall and septal thicknesses with linear contour. The myocardium presented some echogenic remodeling consistent with expected age-related change. Contractility of the ventricular walls was adequate and in normal range for this breed and patient size. The left ventricular outflow tract demonstrated normal laminar flow with subjectively unremarkable structure. Normal measured LVOT. Subjective assessment of the right atrium and auricle revealed normal size, structure and content. No evidence of masses was noted. Tricuspid valvular assessment demonstrated expected findings for this age patient. No obvious TR on Doppler. The right ventricle was of normal size (1/3 diameter of LV), echogenicity and thickness. Pulmonic tract assessment revealed normal valve structure, laminar flow, and diameter (approx.1:1 pa/ao ratio). Normal measured RVOT. No dilation due to heartworm disease, cor pulmonale, stenosis, or pulmonic hypertension was noted. No visible pericardial or free pleural fluid was noted. The mediastinum was free of masses in the visible window.

**ULTRASONOGRAPHIC FINDINGS**

Primary



**PATIENT**

- Normal cardiac structure / function with mild ventricular remodeling

Bax Bough

**INTERPRETATION OF THE FINDINGS & FURTHER RECOMMENDATIONS**

**SPECIES**

No evidence of clinical issues such as left or right heart chamber enlargement, LV systolic dysfunction, overt significant valvular insufficiencies, HCM criteria or other structural cardiomyopathy. No indication for cardiac medications. If a murmur is noted, a benign flow murmur is probable although a small flow abnormality cannot be excluded. Regardless, if present, the hemodynamic effects of a potential murmur are low.

Feline

**BREED**

DLH

No anesthetic contraindications. The following protocol is suggested. Recheck echo recommended in 6 to 12 months, sooner if persistent murmur is noted or if clinical signs consistent with heart disease arise.

**SEX**

MN

Suggested anesthetic protocol may include opioid or Benzodiazepine pre-med, induction with Propofol or Alfaxalone, and appropriate gas anesthesia with avoidance of alpha 2 agonists.

**AGE**

14yr

**WEIGHT**

15.45lb

**INTERPRETED BY**

R. McKenzie Daniel,  
 DVM, DABVP  
 (Canine and Feline)

**IMAGING PERFORMED BY**

Rebecca Hamilton

**HOSPITAL NAME**

Creekside VC Oregon

**REFERRING VET**

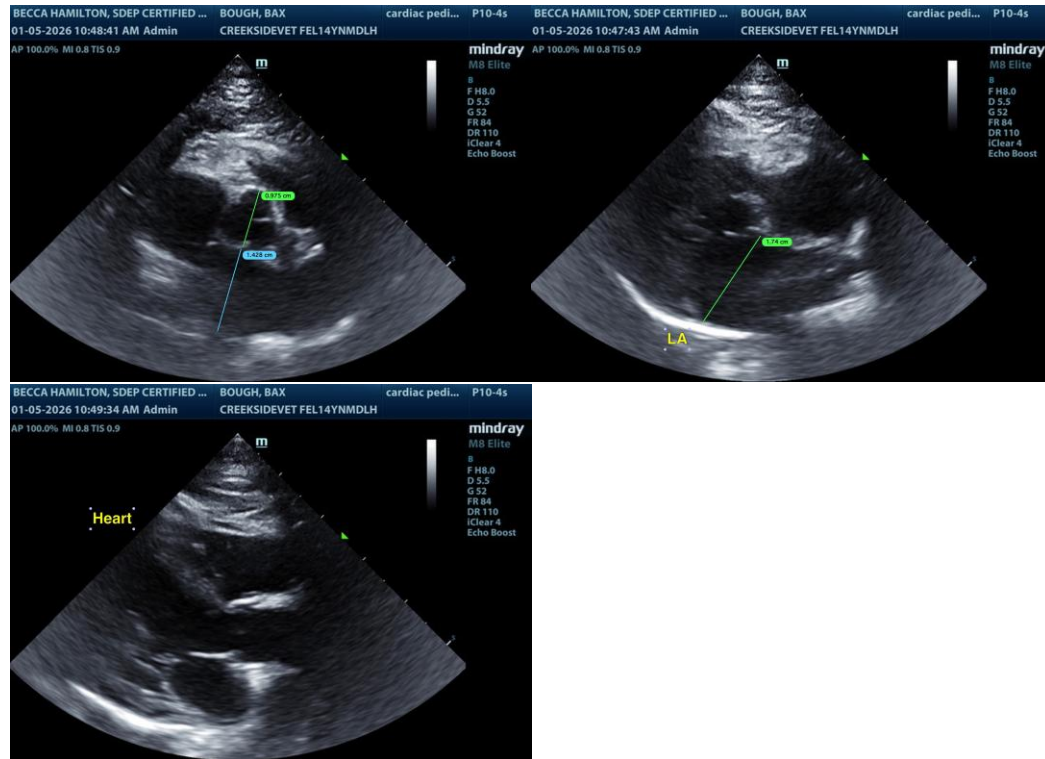
Dr Matteson

**INVOICE**

23456

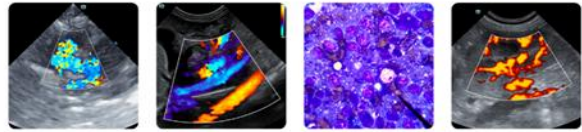
**DATE**

01/05/2026



The information and recommendations provided are based on the images presented by the referring veterinarian/sonographer. No evaluation can be communicated regarding pathology that was not visible in the image/video clips provided.

Thank you for this referral. If the clinical or image interpretation does not parallel your findings or if I can be of any further assistance, please contact me.



**PATIENT**

Bax Bough

R. McKenzie Daniel, DVM, DABVP (Canine/Feline Practice)

[info@sonopath.com](mailto:info@sonopath.com)

**SPECIES**

Feline

**BREED**

DLH

**SEX**

MN

**AGE**

14yr

**WEIGHT**

15.45lb

**INTERPRETED BY**

R. McKenzie Daniel,  
DVM, DABVP  
(Canine and Feline)

**IMAGING  
PERFORMED BY**

Rebecca Hamilton

**HOSPITAL NAME**

Creekside VC Oregon

**REFERRING VET**

Dr Matteson

**INVOICE**

23456

**DATE**

01/05/2026